



Original Article

Amniotic fluid embolism: a catastrophic incident in pregnancy

 Doğuş Özdemir Kara

Turkish Council of Forensic Medicine Ankara Head Office, Department of Pathology, Ankara, Turkey.

Abstract

Objective: Amniotic fluid embolism (AFE) is a rare entity that occurs during pregnancy, about which there is limited information currently. This study aimed to contribute to the literature by evaluating histopathologic findings, clinical data, and autopsy findings of the cases from a postmortem point of view.

Methods: A 10-year retrospective study was designed to assess deaths during pregnancy. To address vascular structures and identify the squamous cells, immunohistochemical staining was performed on the lung specimens of individuals who underwent autopsy due to sudden death during this period and were diagnosed with amnion embolism. Demographic data and clinical findings of the cases were obtained from the institutional archive and evaluated together with autopsy and histopathologic findings.

Results: During a 10-year period, 89 pregnant women were autopsied and five were diagnosed with amniotic fluid embolism. In all cases, macroscopic examination revealed subpleural petechial hemorrhages in the lungs, and hematoxylin-eosin (HE)-stained sections of the lungs showed scales and squamous cells in pulmonary vessel lumens. Immunohistochemical staining with CD34 in vascular structures and with pankeratin (PANCK) in scales and squamous cells was detected in all cases. There was no pathology in other organs on macroscopic and microscopic examination. No drugs or toxins were detected in the blood and body fluids in the toxicologic analysis. Two decedents had symptoms before labor and two decedents had symptoms during labor. One decedent had symptoms just after she gave birth vaginally. Four of them had emergency c-sections. In three cases, uterine rupture followed by hysterectomy was observed, and in two cases, the fetus also died with the mother. Three fetuses whose mothers died due to amniotic fluid embolism were rescued alive.

Conclusion: This study underlines uterine rupture and Cesarean sections as crucial risk factors for AFE, but no connection was found with older maternal age. Although AFE is such a devastating picture, there is still no agreed diagnostic definition currently. This study supports the reliability of the clinical parameters recommended in the Paris AFE framework, which was based on clinical findings. These criteria can also be used in our country in places with more limited conditions. This study emphasizes that it is critical to evaluate patients with echocardiography, which is available in many centers in Turkey, in cases of pregnancy with unstoppable vaginal bleeding that starts with hypotension and neurological findings. The postmortem data can contribute to the recognition of its unique clinical and histopathological manifestations, which can be used for maternal and infant survival.

Keywords: Amniotic fluid, autopsy, embolism, histopathology, postmortem, pregnancy.

Address for correspondence: Doğuş Özdemir Kara, Turkish Council of Forensic Medicine Ankara Head Office, Keçiören, 06300, Ankara, Turkey.

Phone: +90 312 340 73 24 **E-mail:** dogusdr@yahoo.com **ORCID:** 0000-0002-3169-3538

Received: 8 September 2023 **Revised:** 25 September 2023 **Accepted:** 12 October 2023 **Published:** 20 October 2023

OPEN ACCESS This is an open access article under the CC BY-NC license (<http://creativecommons.org/licenses/by-nc/4.0/>).



INTRODUCTION

Amniotic fluid embolism (AFE) was first described by Mayer in 1926 and is a rare entity that occurs when amniotic fluid, fetal cells, lanugo or other debris material from ruptured placental membranes enter the maternal circulation through uterine veins (1). AFE, which is observed during labor or in the immediate postpartum period, is an emergency condition that presents itself with sudden, deep, and unexpected hypotension, dyspnea, hypoxemia, and disseminated intravascular coagulopathy (DIC) in pregnant women, although the clinical picture varies. (1,2). It is a fatal complication with a dramatic clinical picture of sudden onset and rapidly developing cardiopulmonary failure. Various studies have reported the incidence of AFE as 2-6/100,000 and 1/40,000, and the mortality rate between 20% and 60% (1,3). Most patients with AFE are lost in the first few hours following the onset of symptoms and permanent neurologic sequelae are observed in survivors (4). In infants with AFE, mortality has been reported to be approximately 30% (5). AFE has also been reported during labor, early gestational weeks, second-trimester abortions, amniocentesis, or after closed abdominal trauma (5). Postmortem diagnosis of cases with AFE is based on the presence of fetal scales, squamous cells and/or debris in the pulmonary circulation by microscopic examination (6).

The objective of this study is to share with our colleagues the information and postmortem findings of an entity that is one of the rare causes of sudden death in pregnant women and whose precise diagnosis is made by postmortem histopathological examination.

MATERIALS AND METHODS

This is a retrospective study that was conducted in accordance with the Helsinki Declaration. It was reviewed and approved by our review board and ethics committee (No. 21589509/2023/371) on June 15, 2023.

A 10-year retrospective review of pregnancy deaths was analyzed from the archives of our institution. Among all causes of death of pregnant women, individuals whose cause of death was finalized as sudden death were chosen. After detailed medicolegal autopsy, organ samples were sent to the pathology laboratory. All tissue samples sent to the histopathology laboratory were fixed in 10% buffered formalin. The specimens were then sampled by a pathologist. The samples were embedded in paraffin blocks after automatic tissue tracking (Tissue-Tek VIP 6AI, Vacuum infiltration tissue processor/Sakura). Sections obtained from paraffin blocks were stained with hematoxylin and eosin (HE) in an automatic staining-capping device (Tissue-Tek Prisma, Slide Stainer/Sakura). All hematoxylin and eosin-stained slides were evaluated under a light microscope (Nikon Eclipse, Ci/Tokyo Japan) by a pathologist. The study included cases with fetal squamous-amniotic cells and/or mucin in the pulmonary vessels in HE-stained lung slides. Then, immunohistochemical staining with CD34 (rabbit monoclonal antibody, QBEND-10, Bio Genex) to stain vascular structures and pankeratin (mouse monoclonal, Cytokeratin Coctail AE1-AE3, Bio SB) was performed in the lung specimens of the decedents included in the study to identify squamous cells and scales.

Age, pregnancy and gynecological history, clinical information and laboratory findings of the cases were obtained from the archives of our institution. Medical findings and demographic information, histopathological results and autopsy findings were evaluated together.

RESULTS

In a 10-year period, 89 pregnant women were autopsied and five of these cases were diagnosed with amniotic fluid embolism. In three of these cases, uterine rupture was detected through autopsy. The uterus was macroscopically intact in the other cases. In all cases, macroscopic examination revealed subpleural petechial hemorrhages in the lungs and routine hematoxylin-eosin (HE) staining was performed after extensive sampling of the lung and tissue follow-up. The HE-stained sections of the lung were evaluated under a light microscope by a pathologist. In the HE-stained slides of five cases, we observed scales and squamous cells of the fetus and amniotic membrane mixed with erythrocytes and occasionally mucoid material mixed with cells in small, medium and large diameter pulmonary vascular lumens (Figures 1,2). In the immunohistochemical study, staining was identified in vascular structures with CD34 (Figure 3), and in scales and squamous cells were stained with pankeratin (PANCK) (Figure 4).

In the surrounding parenchyma, we observed emphysematous enlargements and fibrin microthrombus formations within vascular structures supporting disseminated intravascular coagulation (DIC) (Figure 5).

No pathological findings were observed in other organs on macroscopic and microscopic examination. There were no drugs or toxins in the blood and body fluids in the toxicological analysis.

The youngest patient was 18 years old and the oldest patient was 43 years old. Two of the cases were followed up due to overdue pregnancy. Three cases were primiparous (first pregnancy) (Table 1). One patient had a history of oligohydramnios and the other patients had no previous medical history. Two of the decedents in the present study had symptoms before labor and two decedents had symptoms during labor. Four of them all had emergency c-sections. One decedent had symptoms just after she gave vaginal birth. Two of the decedents had a history of presentation to the emergency department with symptoms of hypotension, confusion and fainting before labor. Two deceased had hypotension, tachycardia, and cardiac failure, which started during labor. Three cases had a history of unstoppable vaginal bleeding and uterine rupture and hysterectomy had to be performed. In one case, postnatal onset of confusion, hypotension and unstoppable vaginal bleeding were observed. Since all of the deceased were admitted to peripheral health institutions, the c3-c4 level was not checked in any of them. In all cases, there was a history of arrest with sudden onset in the clinic and rapid deterioration. In three decedents who had had uterine rupture before, shock and DIC were present in their medical history (Table 1). In three cases, uterine rupture was followed by hysterectomy and two fetuses died together with the mother. Three fetuses whose mothers died due to AFE were rescued alive.

Table 1. Clinical and pathological features of the cases

Case number	Age	Gestational age (week)	Numbers of birth	Histopathological findings	Time of onset of symptoms	Other clinical data	Mode of delivery	Neonatal alive or dead
1	22	37	1	Squamous cell in the pulmonary vascular structures	During labor	Uterine rupture and bleeding DIC	Cesarean	Alive
2	18	37	1	Squamous cell in the pulmonary vascular structures	Before labor	Uterine rupture and bleeding DIC	Cesarean	Dead
3	34	38	2	Squamous cell in the pulmonary vascular structures	Before labor	No	Cesarean	Alive
4	25	42	1	Squamous cell in the pulmonary vascular structures	During labor	Oligohydroamnios vaginal bleeding, uterine rupture DIC	Cesarean	Dead
5	43	42	3	Squamous cell in the pulmonary vascular structures	After the labor	Vaginal bleeding	Vaginal delivery	Alive

Abbreviations: DIC: Disseminated intravascular coagulation

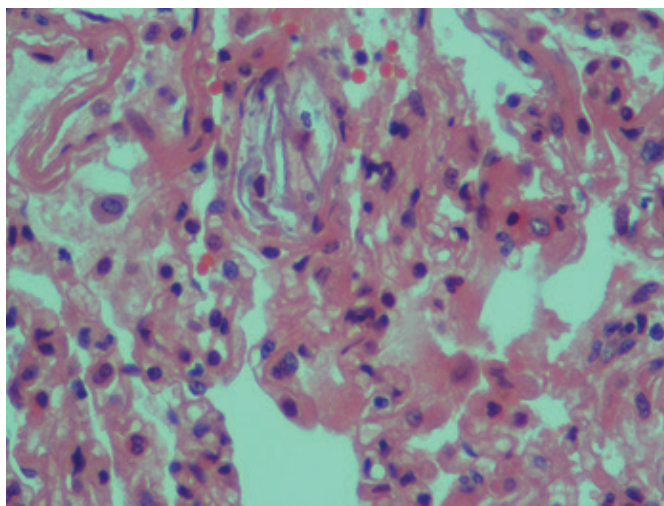


Figure 1. Squamous cells, scales and mucoid material are seen inside the lumen of pulmonary vascular structures, HE, X20

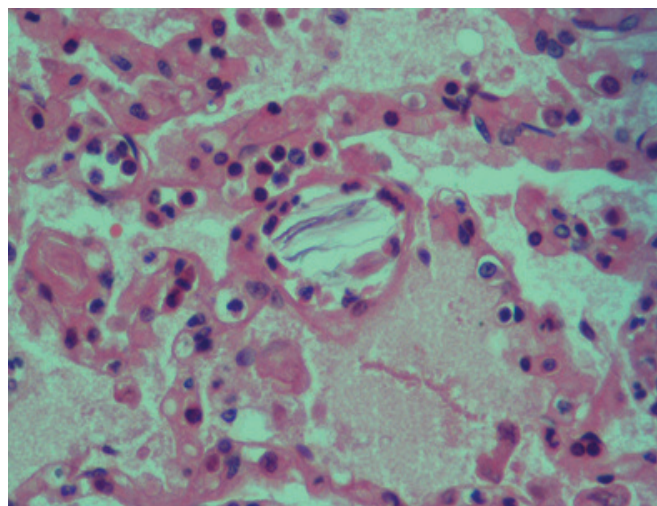


Figure 2. Squamous cells, scales and mucoid material are seen inside the lumen of pulmonary vascular structures, HE, X20

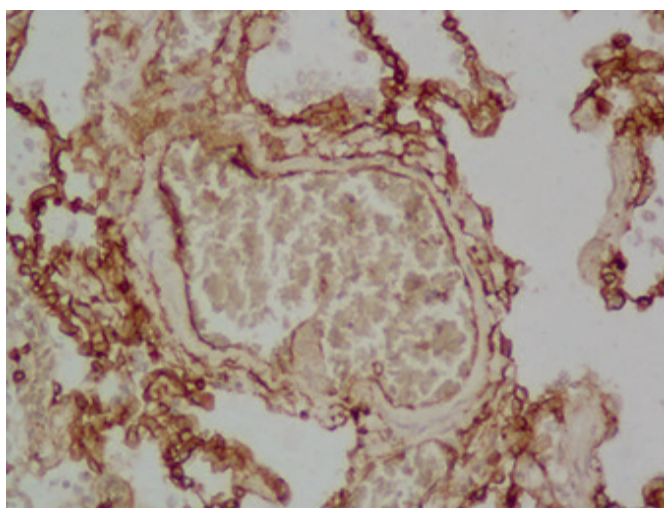


Figure 3. Pulmonary vascular structure is revealed by immunohistochemical staining with CD34, X20

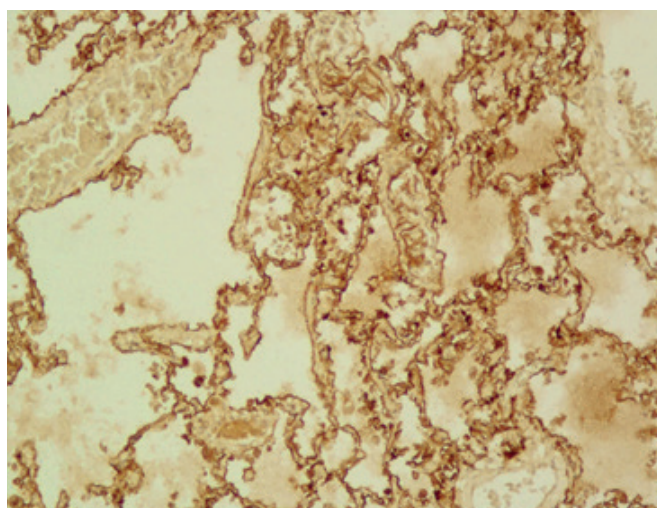


Figure 4. Inside the lumen of pulmonary vascular structures, squamous cells and scales are identified by immunohistochemical staining with pankeratin, X20

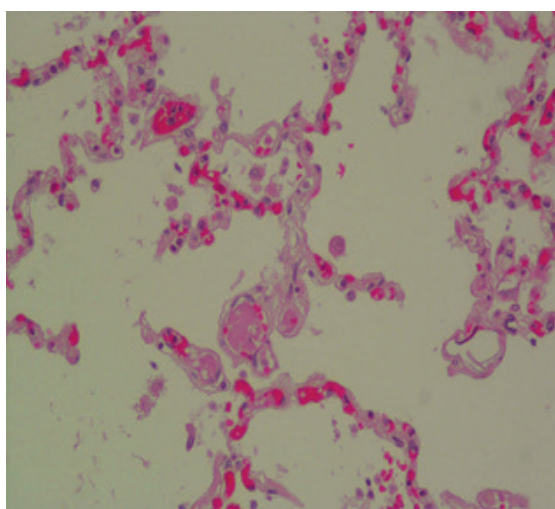


Figure 5. Fibrin microthrombi are evident in the lumen of capillaries, and small caliber vascular structures offering a good finding for disseminated intravascular coagulation, HE, X20

DISCUSSION

The incidence varies widely, ranging from 1/8000 to 1/80000 in some studies due to different diagnostic approaches, inappropriate classification, and reporting of nonfatal cases (5,7). The etiology and pathophysiology of amniotic fluid embolism have not been fully elucidated. It might be observed in women who were healthy until that moment, after delivery, during Cesarean section, problematic vaginal delivery, miscarriage, abdominal trauma, amnion infusion, or in the second trimester of pregnancy (5). It even might occur up to 48 hours after delivery (5). One study found that 70% of cases occurred during delivery, 11% after delivery, and 19% after Cesarean section (8). In the present study, a sudden and severe clinical picture started during Cesarean section in two cases (40%), during vaginal delivery in one case (20%) and before labor in two cases (40%). In its first characterization, pathophysiology was described as mechanical obstruction of the vascular structures caused by the amniotic fluid, fetal cells, hair, and other debris into the maternal circulation, followed by cardiovascular collapse (2,9). Nevertheless, it is now suggested that the classical systemic inflammatory response triggered by proinflammatory mediators against fetal structures due to disruption of the fetomaternal barrier is more impactful than a simple mechanical obstruction of the circulation (1). Fetal elements enter the maternal systemic circulation, causing an abnormal and exaggerated immune response. The role of complement system activation in this immune response has also been described. The data analysis showed two types of AFE. Type I is characterized by circulatory collapse due to mechanical obstruction of the pulmonary circulation by fetal material. Type II, however, is caused by an anaphylactoid-like reaction to fetal material, leading to pulmonary vasospasm and activation of platelets, white blood cells, and the complement system, which can lead to DIC and atonic uterine bleeding (9). In the present study, two of the presented cases had classical type clinical findings, whereas three had (60%) postmortem DIC findings. Clinical findings of AFE include acute dyspnea, cough, hypotension, cyanosis, fetal bradycardia, encephalopathy, acute pulmonary hypertension, and coagulopathy since it affects many organs (5). Based on the pattern of clinical symptoms and severity of the disease, a classification has been suggested as classical type, disseminated intravascular coagulopathy (DIC type), and anaphylactoid type. The clinical pictures of two decedents in the study were compatible with the classical type, while the DIC picture was prominent in three decedents.

The authors validated a significant correlation between several variables, including maternal, pregnancy and birth characteristics, with known factors (the most important being placental abruption, advanced maternal age and preterm delivery) and established the influence of the placenta accreta spectrum (PAS) (10). However, placenta-related pathologies, the most important risk factor, were not detected in this study.

In another study, while similar risk factors were reported, there was no risk factor in many cases (11). In the present study, one advanced maternal age was established; for the rest, four cases were young expectant mothers (80%). In an American report, similar to the present study, Cesarean section and uterine rupture were found to be important risk factors for AFE (12). In this study, four of the decedents who had Cesarean sections and two decedents had symptoms before the Cesarean operation. Therefore, only two cases can be attributed to the Cesarean section procedure. Later pregnancies were not associated with AFE recurrence (13). Since AFE affects many systems, it is diagnosed clinically by excluding other entities (14). Furthermore, in cases of suspicion, simple lung imaging, serum tryptase level, serum C3-C4 complement levels, zinc coproporphyrin-1, and serum sial Tn (STN) levels were reported to be useful in making the diagnosis (5). A study noted that zinc coproporphyrin levels increased in the clinical type in which cardiopulmonary collapse was prominent, whereas C3 and C4 levels decreased in cases in which the DIC picture was prevalent (15). C1 esterase inhibitor is a major inhibitor of C1 esterase and can suppress plasma kallikrein as well as factors XIIa and XIa. Its efficacy was considerably lower in pregnancy and labor than in the nonpregnant state. Low C1 esterase inhibitor activity levels were highly correlated with the pathogenesis of amniotic fluid embolism and the C1 esterase inhibitor level had potential as a prognostic indicator of amniotic fluid embolism (7). The Society of Maternal Fetal Medicine (SMFM) and the Amniotic Fluid Embolism Foundation (AFEF) have suggested four essential diagnostic features for AFE: (a) presence of sudden cardiac arrest or both respiratory and hemodynamic collapse, (b) biological DIC, (c) absence of fever, and (d) clinical onset during labor or within 30 minutes after delivery (16). Using these criteria, Bonnet et al. found that only 58% of their patients met all four criteria in their French study (Paris AFE framework). Therefore, they recommended a new framework based entirely on clinical findings that were (a) premonitory signs such as

neurological signs, abnormal fetal heart rate or respiratory signs, (b) sudden hypotension or cardiorespiratory arrest, (c) clinical early massive obstetric hemorrhage or clinical DIC, and (d) clinical onset during labor or within 30 min of delivery (17). Four patients in the current study had hypotension, and two patients had a clinical picture starting with neurological findings. Three cases had a history of unstoppable vaginal bleeding. Considering that the definitive diagnosis of all cases was confirmed by pathological examination after autopsy, this study supports the reliability of the clinical parameters recommended in the Paris AFE framework. AFE is a catastrophic condition that lacks an agreed-upon definition of the diagnosis. Although several schemes have been proposed for the clinical diagnosis of early AFE, the confirmed diagnosis of AFE is the presence of fetal elements in the pulmonary circulation of the mother after autopsy (16). For postmortem diagnosis of AFE, the authors recommend a double immunohistochemical (anti CD31 and anti-cytokeratin AE1/AE3) stain to assess the amniotic fluid pulmonary embolic burden accurately. This method is a highly reproducible and an easy way to detect scales within the lung vasculature (18). This present study used anti-CD34 (which can also be used for vasculature staining) and pankeratin (AE1/AE3/for scales and skuamos cells) to confirm AFE diagnosis (Figure 3, Figure 4). In a meta-analysis evaluating echocardiographic findings in AFE, cardiovascular collapse stemmed from right ventricular failure. Biventricular dysfunction was observed in 13% of cases, while 67% had right ventricular dysfunction. Therefore, right ventricular dysfunction is an important parameter when diagnosing AFE and selecting high-risk patients (19). Echocardiographic findings were not available in two of the cases in the study. Among three cases, right ventricular failure was detected in one, while biventricular failure was detected in two.

For rapid treatment, it is recommended to perform transthoracic or transesophageal echocardiography in suspected cases as soon as possible, as these methods are the best and reliably reveal right ventricular failure (20). Maternal treatment is mainly in the form of support and shock treatment, and in cases of cardiovascular collapse, rapid delivery of the newborn is of critical importance (1). Treatment options include emergency hysterectomy, reoperation with intra-abdominal packing, and intra-aortic balloon pump insertion (3,21). In addition, exchange transfusion, extracorporeal membrane oxygenation, and uterine artery embolization have been tried from time to time (5,21). One study suggested that treatment of hyperfibrinolysis and hypofibrinogenaemia may improve AFE outcome (22). Despite newly tried treatment methods, studies have shown a mortality rate of 61% and a permanent neurologic sequelae rate of 85% in AFE, the most common cause of maternal mortality in some countries (4,8,23). AFE is a crucial cause of intrauterine fetal death and fetal death during labor. In a study conducted in Australia and New Zealand, the perinatal mortality rate was found to be 202/1000 (23).

Limitations:

This study has some limitations. The sample size of the study is small. It would be more appropriate to conduct the study with larger case series. Detailed laboratory results of the cases could not be obtained, which prevented discussing these results.

CONCLUSION

This study can contribute to the literature on the related subject given that there are still many unanswered questions regarding AFE, and there is a lack of knowledge and experience in many aspects of the subject. This study points out uterine rupture and Cesarean sections as crucial risk factors for AFE. Although AFE is such a devastating picture, there is still no agreed diagnostic definition currently. Considering that the definitive diagnosis of all cases was confirmed by pathological examination after autopsy, this study supports the reliability of the clinical parameters recommended in the Paris AFE framework. These criteria can also be used in our country in places with more limited conditions. This study reveals that although there is no definitive method for the diagnosis of AFE, it is critical to evaluate patients with echocardiography, which is available in many centers in Turkey, in cases of pregnancy with unstoppable vaginal bleeding that starts with hypotension and neurological findings. Since there are many unknown parameters in this entity, all studies on the subject are crucial. The current study aims to introduce this entity, which medical pathologists do not have much opportunity to see, and to remind clinicians of this rare entity with different aspects. Postmortem data can help the recognition of its unique clinical and histopathological manifestations, which can be used for maternal and infant survival.

Conflict of interest: The author declares that no conflicts of interest.

Ethics committee approval: This study was reviewed and approved by our review board and ethics committee (No. 21589509/2023/371) on June 15, 2023.

Financial disclosure: This study did not receive any specific grants from funding agencies in the public, commercial, or not-for-profit sector.

Peer-review: Externally peer-reviewed.

Authorship contributions: Concept, design, supervision, funding, materials, data collection &/or processing, analysis and/or interpretation, literature review, writing and critical review: D.O.K.

References

- Shamshirsaz AA, Clark SL. Amniotic Fluid Embolism. *Obstet Gynecol Clin North Am.* 2016;43:779-90.
- Coggins AS, Gomez E, Sheffield JS. Pulmonary Embolism and Amniotic Fluid Embolism. *Obstet Gynecol Clin North Am.* 2022;49:439-60.
- Kristensen K, Langdana F, Clentworth H, Hansby C, Dalley P. Amniotic fluid embolism after intrauterine fetal demise. *N Z Med J.* 2016;129:87-8.
- Kaur K, Bhardwaj M, Kumar P, Singhal S, Singh T, Hooda S. Amniotic fluid embolism. *J Anesthesiol Clin Pharmacol.* 2016;32:153-9.
- Tsunemi T, Hidekazu OI, Sado T, Naruse K, Noguchi T, Kobayashi H. An overview of amniotic fluid embolism: Past, present and future directions. *Open Womens Health J.* 2012;6:24-9.
- Knight M, Tuffnell D, Brocklehurst P, Spark P, Kurinczuk JJ. UK Obstetric Surveillance System. Incidence and risk factors for amniotic-fluid embolism. *Obstet Gynecol.* 2010;115:910-7.
- Tamura N, Kimura S, Farhana M, Uchida T, Suzuki K, Sugihara K, et al. C1 esterase inhibitor activity in amniotic fluid embolism. *Crit Care Med.* 2014;42:1392-6.
- Sultan P, Seligman K, Carvalho B. Amniotic fluid embolism: update and review. *Curr Opin Anesthesiol.* 2016;29:288-96.
- Barakat M, Alamami A, Ait Hssain A. Recurrent Cardiac Arrests Due to Amniotic Fluid Embolism. *Cureus.* 2022;14:22475.
- Cavoretto PI, Rovere-Querini P, Candiani M. Toward Risk Assessment for Amniotic Fluid Embolisms. *JAMA Netw Open.* 2022;5:2242850.
- Kamata M, Maruyama T, Nishiguchi T, Iwasaki S. Sudden onset of syncope and disseminated intravascular coagulation at 14 weeks of pregnancy: a case report. *BMC Pregnancy Childbirth.* 2020;20:406.
- Mazza GR, Youssefzadeh AC, Klar M, Kunze M, Matsuzaki S, Mandelbaum RS, et al. Association of Pregnancy Characteristics and Maternal Mortality With Amniotic Fluid Embolism. *JAMA Netw Open.* 2022;5:2242842.
- Cahan T, De Castro H, Kalter A, Simchen MJ. Amniotic fluid embolism - implementation of international diagnosis criteria and subsequent pregnancy recurrence risk. *J Perinat Med.* 2021;49:546-52.
- Kanayama N, Tamura N. Amniotic fluid embolism: pathophysiology and new strategies for management. *J Obstet Gynecol Res.* 2014;40:1507-17.
- Pacheco LD, Clark SL, Klassen M, Hankins GDV. Amniotic fluid embolism: principles of early clinical management. *Am J Obstet Gynecol.* 2020;222:48-52.
- Buechel J, Monod C, Alba Alejandre I, Ninke T, Hoesli I, Starrach T, et al. Amniotic fluid embolism: A comparison of two classification systems in a retrospective 8-year analysis from two tertiary hospitals. *J Gynecol Obstet Hum Reprod.* 2023;52:102597.
- Bonnet MP, Zlotnik D, Saucedo M, Chassard D, Bouvier-Colle MH, Deneux-Tharoux C. French National Experts Committee on Maternal Mortality. Maternal Death Due to Amniotic Fluid Embolism: A National Study in France. *Anesth Analg.* 2018;126:175-82.
- Zhu C, Xu D, Luo Q. Fatal amniotic fluid embolism: incidence, risk factors and influence on perinatal outcome. *Arch Gynecol Obstet.* 2023;307:1187-94.
- Wiseman D, Simard C, Yang SS, Koolian M, Abenhaim HA, Lipes J. Echocardiography findings in amniotic fluid embolism: a systematic review of the literature. *Can J Anaesth.* 2023;70:151-60.
- McDonnell N, Knight M, Peek MJ, Ellwood D, Homer CS, McLintock C, et al. The Australasian Maternity Outcomes Surveillance System (AMOSS). Amniotic fluid embolism: an Australian-New Zealand population-based study. *BMC Pregnancy Childbirth.* 2015;15:352.
- Benson MD. Current concepts of immunology and diagnosis in amniotic fluid embolism. *Clin Dev Immunol.* 2012;2012:946576.
- Oliver C, Freyer J, Murdoch M, De Lloyd L, Jenkins PV, Collis R, et al. A description of the coagulopathy characteristics in amniotic fluid embolism: a case report. *Int J Obstet Anesth.* 2022;51:103573.
- Tombolini A, Broglia I, Ferrara G. Technical note: double immunohistochemical stain (anti-CD31 and anti-cytokeratins) as a tool for a confident forensic postmortem diagnosis of amniotic fluid embolism. *Int J Legal Med.* 2021;135:355-7.