



Original Article

The value of second-look ultrasonography for magnetic resonance imaging-detected suspicious breast lesions in patients with breast cancer

 Sibel Aydın Aksu

Haydarpaşa Numune Training and Research Hospital, Department of Radiology, İstanbul, Turkey.

Abstract

Objective: Breast magnetic resonance imaging (b-MRI) is a highly sensitive diagnostic tool for detecting breast cancer (BC), but its relatively low specificity often requires tissue sampling. This study aimed to assess the utility and efficacy of second-look ultrasound (SLUS) in evaluating incidentally enhancing lesions (IELs) identified by preoperative contrast-enhanced breast MRI (CE-bMRI) and to review our institutional experience.

Methods: The study enrolled histopathologically proven invasive BC patients, who underwent preoperative CE-bMRI for cancer staging and were scanned with SLUS for IELs detected on MRI. The lesions' imaging features and morphological analyses were assessed using the Breast Imaging and Reporting and Data System (BI-RADS). According to the BI-RADS classification, IELs considered Category 3 or 4 and had a suspicious correlate on SLUS were biopsied immediately.

Results: Additional IELs were detected in 121 of 352 (34.37%) patients on preoperative CE-bMRI, which was performed for staging. One hundred thirteen lesions were SLUS-correlated. BI-RADS Category 2 and 3 lesions were managed conservatively, while Category 4 lesions were biopsied under imaging guidance. The majority of the IELs were ipsilateral with known BC (61.00%), unifocal (62.26%), and showed mass enhancement, classified as BI-RADS 4 (57.23%) with indistinct and spiculated margins (71.68%). SLUS yielded a detection rate of 68.59%.

Conclusion: SLUS may be a valuable tool in evaluating lesions initially detected in breast MRI and can help reduce unnecessary biopsies.

Keywords: Breast cancer, magnetic resonance imaging, ultrasonography.

INTRODUCTION

Contrast-enhanced breast MRI (CE-bMRI) has high sensitivity but relatively low specificity, ranging from 40% to 80%. It is the most sensitive diagnostic tool for detecting and staging malignant breast lesions (1,2). In 16% of women with histologically proven breast cancer, preoperative MRI reveals additional lesions and leads to changes in the surgical procedure (3). It is, however, challenging to diagnose additional lesions detected during MRI. Because MR-guided vacuum-assisted biopsy of the breast has limited availability and a high cost, many MRI-detected lesions are evaluated by second-look ultrasound (SLUS) (4). In a woman with unilateral breast cancer (BC), the prevalence of synchronous contralateral cancer is approximately 1% to 4%, and MRI can detect clinically and mammographically occult contralateral cancers in 3% to 9% of cases (5,6). A well-timed diagnosis of contralateral cancer at the time of ipsilateral cancer is critical, as bilateral synchronous cancers are associated with better survival and an earlier stage of cancer (6-9). SLUS is used in clinical practice to re-evaluate the additional suspicious or indeterminate lesions of previously undetected, newly revealed by CE-bMRI. The primary role of SLUS is to locate the MRI-detected lesion and obtain histologic verification with US-guided instead of MR-guided biopsy (2,4).

This study aimed to assess the usefulness and efficacy of SLUS in evaluating incidental enhancing lesions (IELs) identified by preoperative CE-bMRI performed for breast cancer staging and to provide an overview of our institutional experience.

MATERIALS AND METHODS

Ethical consideration

This study was conducted following the principles of the Helsinki Declaration and the study protocol was approved by the Institutional Review Board of Haydarpasa Numune Research and Training Hospital (file date and number: 2021/168-3339).

Patient selection

Between October 2021 and April 2023, the study enrolled 352 histopathologically proven invasive breast cancer patients who underwent preoperative breast MRI for cancer staging and were scanned with SLUS for IELs detected on MRI. The study design is given in the flowchart (Figure 1). Images were recalled from the Picture Archiving and Communication System (PACS) and reviewed by one breast radiologist with seven years of experience and board-certified in breast imaging. The study excluded patients who did not have a pathology report in our hospital, were diagnosed with diseases other than primary carcinoma of the breast and received surgery, chemotherapy or radiotherapy prior to imaging.

MRI study

Patients with suspected breast malignancy on digital mammography (MMG) and/or whole-breast US, and subsequently confirmed by core biopsy, underwent preoperative breast MRI for staging. All the cases included in the study were examined with the same 1.5 T MRI scanner (GE Optima 36 Bamboo; General Electric, Milwaukee WI USE) using a dedicated 16-channel phased-array bilateral breast coil in the prone position. A standard imaging protocol designed primarily for cancer staging was utilized. An intravenous bolus injection of 0.1 mmol/kg gadobutrol (Gadovist; Bayer Schering Pharma, Berlin, Germany) was administered at 2 ml/s, followed by a 20-ml saline flush. T2-weighted imaging was performed using two different pulse sequences. The slice thickness was 3 mm. Precontrast, early, and delayed phases, acquired with a scan time of 60-120 seconds per phase 3.5 to 4 minutes (depending on slice number), were performed for dynamic imaging with high spatial resolution. Subtraction images were also obtained. All MRI images were retrospectively reviewed by one board-certified breast radiologist blinded to the previous examinations, such as whole-breast US, MMG, or clinical information. IELs detected on the same side or the opposite side to the known tumor were evaluated in terms of size (the longest diameter on the first or second subtracted axial images and on sagittal/coronal reconstructions), localization (ipsilateral/contralateral) distribution (unifocal/multifocal-multicentric), and enhancement patterns (focus-foci/

mass/nonmass). Morphological analysis was reported using the Breast Imaging Reporting and Data System (BI-RADS) classification. Lesions considered ACR BI-RADS Category 2 and 3 were managed conservatively. Some of the Category 3 lesions needed correlation with SLUS. All suspected IELs detected on CE-bMRI and considered ACR BI-RADS Category 3 and 4 were subsequently examined by SLUS.

SLUS

Within two weeks following CE-bMRI, high-resolution US examinations were conducted in patients with suspected IELs in ACR BI-RADS Categories 3 and 4. SLUS was performed in a half-dark examination room in the supine position by an experienced radiologist. An Applio 500 diagnostic color-Doppler ultrasound system (Toshiba Medical Systems Corporation, Tochigi, Japan) with a 17.5 MHz linear transducer was used. A water-based transmission gel was applied before the procedure. The examination was performed directly at the site of the incidental finding. Visible IELs were analyzed regarding the size (the longest tumor diameter), margins (circumscribed/not circumscribed), and echo pattern (hyperechoic/complex cystic and solid/isoechoic/hypoechoic/heterogeneous) and classified according to the US BI-RADS lexicon. ACR BI-RADS Category 2 and 3 lesions were managed conservatively, while Category 4 lesions were biopsied. Some IELs were not visible on SLUS. This group comprised small lesions with a diameter under 2 mm and nonmass lesions. Therefore, pre-MRI examinations were revisited. MMG-guided stereotactic biopsy was performed on these lesions corresponding to focal asymmetry or hazy amorphous calcifications on the MMG. IELs that were not seen on previous examinations were followed-up with MRI.

Biopsy

IELs considered ACR BI-RADS Category 3 and 4a, 4b, and 4c on CE-bMRI and SLUS were evaluated histopathologically immediately after the US examination. SLUS-correlated lesions underwent tissue sampling with core biopsy or excisional biopsy with wire localization under US guidance. Meanwhile, nonvisible lesions with corresponding findings on MMG underwent stereotactic biopsy or wire localization under the guidance of MMG.

RESULTS

Additional IELs were detected in 121 out of 352 (34.37%) patients on the CE-bMRI performed for staging breast cancer. All the patients were female, with a mean age of 51.40 years and a standard deviation of 8.56 years. Table 1 presents the clinicopathological features of 121 patients. A total of 159 IELs were identified in 121 patients, with a mean size of 7.6 ± 4.6 mm. Table 2 presents the features of IELs detected in DCE-bMRI. Most IELs were ipsilateral with known BC (61.00%) and unifocal (62.26%). Regarding the enhancement pattern of the lesions, 109 (68.55%) masses, 44 (27.68%) nonmasses, and 6 (3.77%) focus/foci enhancements were noted. The MRI BI-RADS lexicon was used to classify the lesions, with 45 (28.13%) classified as BIRADS 3 and 91 (57.23%) classified as BIRADS 4. Forty-six IELs of 38 patients were not evaluated on SLUS. In this group, while 24 IELs of 19 patients did not receive SLUS because they were assigned BI-RADS Category 2 or 3 on MRI, the other 19 patients had 22 sonographically undetectable lesions. These nonvisible IELs comprised small (≤ 2 mm.) or nonmass lesions. One hundred thirteen lesions of 83 patients were identified on SLUS, yielding a detection rate of 68.59%. Of 83 SLUS-correlated patients, 51 (61.44%) had one lesion, 28 (33.73%) had two lesions, and two (4.83%) had three lesions. Table 3 shows the features of SLUS-correlated lesions Table 3. A total of 113 lesions were identified, with a mean size of 6.3 ± 4.2 mm. The lesions mostly had noncircumscribed margins (71.68%) and were predominantly indistinct and spiculated. The echo pattern of the lesions was also recorded. Sixteen lesions (14.16%) showed hyperechoic/complex/cystic and solid patterns, while 97 (85.84%) showed isoechoic/hypoechoic/heterogeneous patterns. The US BI-RADS lexicon was used to classify the lesions. Of the categories assigned, 16 (14.16%) were Category 2, 36 (31.86%) were Category 3, and 61 (53.98%) were Category 4. In SLUS-nonvisible IELs, previous examinations were revisited. Associated features of the lesions detected on MMG were also recorded. The corresponding lesions were one (0.88%) architectural distortion, two (1.77%) focal asymmetries, and one (0.88%) mammographic hazy calcification. Ninety-one of 113 (80.53%) IELs underwent imaging-guided biopsy. Eighty-seven SLUS-correlated

lesions were sampled under US guidance, with core biopsy or excisional biopsy with wire localization. Four sonographically nonvisible lesions that had corresponding findings on MMG underwent stereotactic biopsy or wire localization under the guidance of MMG. Twenty-two (19.47%) lesions were not biopsied since they were scored BI-RADS Category 2 (n=16) and Category 3 (n=6) on SLUS. On histopathological examination, 31 of 91 IELs (34.06%) were malignant, consisting of 18 (19.78%) DCIS and 13 (14.28%) invasive ductal carcinoma (IDC). Seven (38.89%) DCIS cases and four (30.77%) IDC cases were in the contralateral breast. However, the vast majority of IELs were benign. The most common types of benign lesions were fibrocystic changes (n=28, 30.77%), fibroadenomas (n=25, 25.47%), and intraductal papillomas (n=3, 3.29%). The remaining benign lesions were radial scar/complex sclerosing lesions (n=2, 2.19%), LCIS (n=1, 1.10%), and atypical ductal hyperplasia (n=1, 1.10%). Twenty-two of 60 benign lesions (36.66%) were in the contralateral breast.

Table 1. Clinicopathological characteristics of the study population

Features	n	%	Mean±SD
Study population (patient)	352		
IELs (patient)	121	34.37	
Age (years)			51.40±8.56
Biopsied lesions	91	80.53	
Malignant	31	34.06	
	DCIS	18	19.78
	IDC	13	14.28
Benign	60	65.93	
	Fibrocystic changes	28	30.77
	Fibroadenoma	25	25.47
	Intraductal papilloma	3	3.29
	Radial scar/complex sclerosing lesion,	2	2.19
	LCIS	1	1.10
	Atypical ductal hyperplasia	1	1.10

Abbreviations: IELs: Incidental Enhancing Lesions, DCIS: Ductal Carcinoma in situ, IDC: Invasive Ductal Carcinoma, LCIS: Lobular Carcinoma in situ, n: Number, SD: Standard Deviation.

Table 2. Features of IELs detected in Contrast-enhanced breast MRI (DCE-bMRI).

Features	n	%	Mean±SD
IELs (lesions)	159		
Enhancement pattern			
Focus/foci	6	3.77	
Mass enhancement	109	68.55	
Non-mass enhancement	44	27.68	
Distribution			
Unifocal	99	62.26	
Multifocal/multicentric	60	37.74	
Side			
Ipsilateral	97	61.00	
Contralateral	62	39.00	
Size (mm)			7.6±4.6
MRI-BIRADS Lexicon			
BIRADS 3	45	28.13	
BIRADS 4	91	57.23	

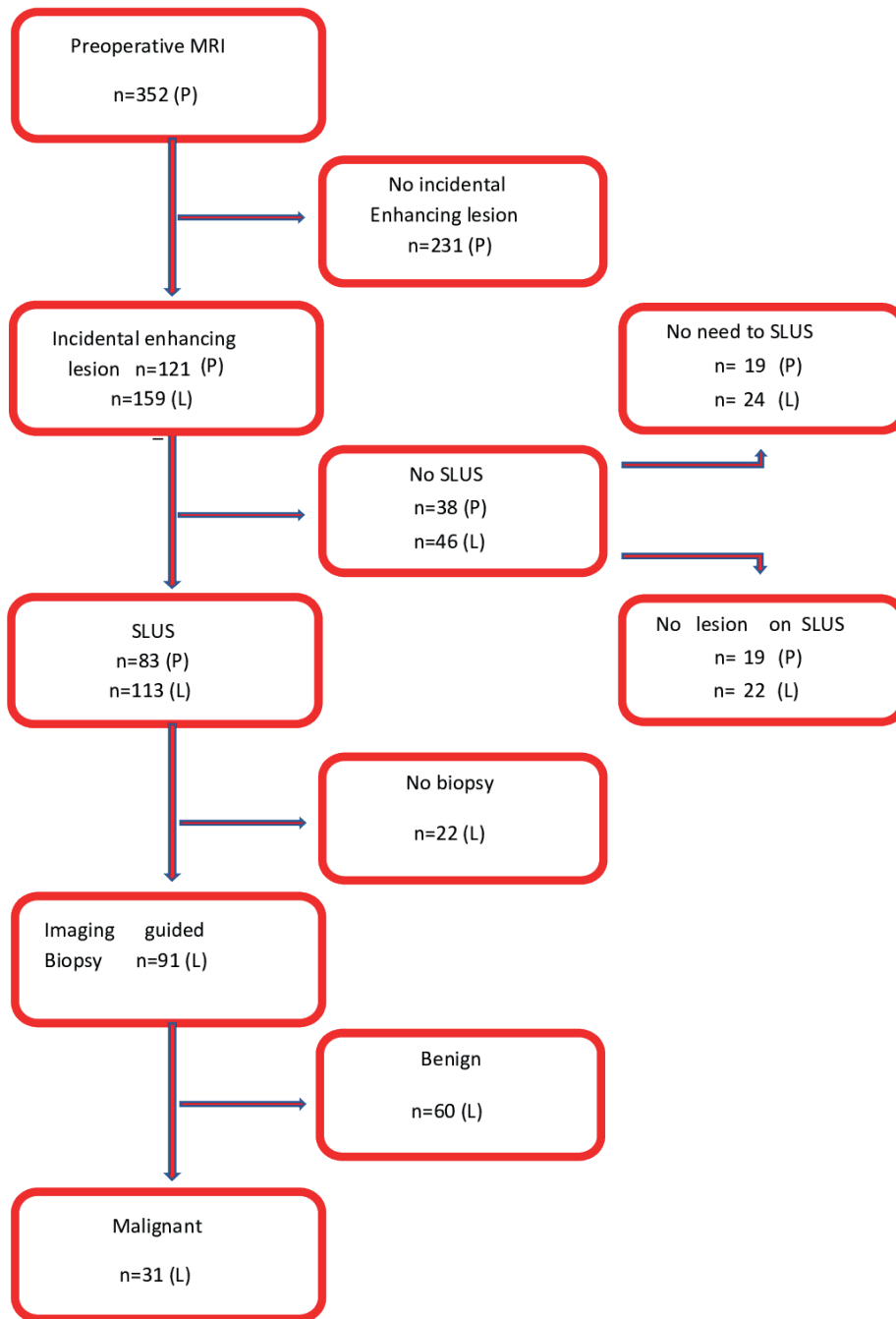
Abbreviations: IELs: Incidental Enhancing Lesions, MRI: Magnetic Resonance Imaging, BI-RADS: Breast Imaging Reporting and Data System, n: Number, SD: Standard Deviation.

Table 3. Features of Second Look Ultrasonography (SLUS) correlated lesions.

Features	n	%	Mean±SD
SLUS correlated lesions	113		
Size (mm)			6.3±4.2
Margins			
	Circumscribed	32	28.32
	Not-circumscribed	81	71.68
Echo pattern			
	Hyperechoic/complex cystic and solid	16	14.16
	Isoechoic/hypoechoic/heterogeneous	97	85.84
US-BIRADS Lexicon			
	Non-visible	22	13.83
	BIRADS 2	16	14.16
	BIRADS 3	36	31.86
	BIRADS 4	61	53.98
Associated features			
	Architectural distortion	1	0.88
	Focal asymmetry	2	1.77
	Mammographic hazy calcifications	1	0.88

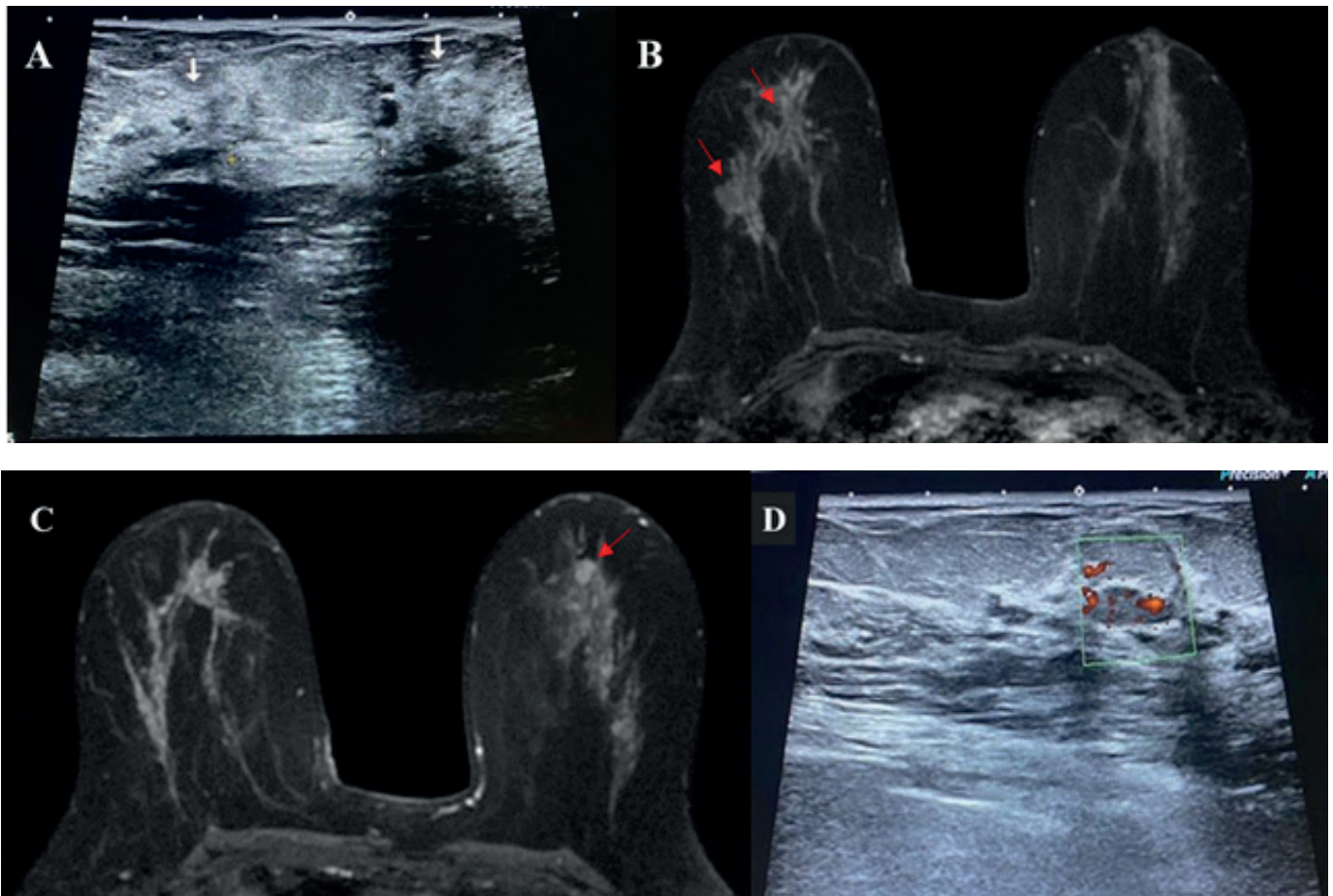
Abbreviations: SLUS: Second Look Ultrasonography, BI-RADS: Breast Imaging Reporting and Data System.

Figure 1. Flowchart of the study



Abbreviations: (P): Patients, (L): Lesions

Figure 2. 62-year-old woman with newly diagnosed right breast invasive ductal carcinoma.



A. Whole-breast sonography showed two hypoechoic masses with irregular shape and indistinct margins at the 9-O'clock position in the right breast (red arrows).

B. Preoperative CE-bMRI was performed for staging purposes. Axial postcontrast T1W MR image showed two spiculated-irregular shaped, mildly enhancing masses at the 9-O'clock position in the right breast corresponding the US lesions (red arrows). Between the two masses, a nonmass-enhancement area representing insitu ductal component was attracted attention which was not detected on initial sonography.

C. An additional enhancing nodule was noticed at the 12-O'clock position in the left breast, which was not detected on the initial sonography.

D. SLUS was performed. An isoechoic nodule with an oval shape and indistinct margin was observed. On Color Doppler Ultrasound, the mass showed arterial vascular foci. Subsequent US-guided core needle biopsy revealed invasive ductal carcinoma in the contralateral breast.

DISCUSSION

Breast MRI is a highly sensitive diagnostic tool for detecting breast cancer, but its relatively low specificity often requires tissue sampling. MR-guided vacuum-assisted breast biopsy is an accurate tool, but its use is limited by low availability and high cost (10). Combining MRI and SLUS may be more effective in preventing cancers from being overlooked than using US alone or US followed by MRI. Previous studies have reported that SLUS after CE-bMRI has detection rates ranging from 23% to 86.8% (11-14). In our study, we achieved a detection rate of 68.59%. Consistent with the literature, the detection rate was higher for mass than for nonmass lesions and correlated with lesion size (15-17). The size of the lesion is closely related to detectability on imaging. In our study, some of the nonvisible IELs on SLUS were less than 2 mm in diameter, while the mean size of IELs was 7.6 ± 4.6 mm for lesions detected on MRI and 6.3 ± 4.2 mm for those correlated with SLUS. Furthermore, the lesion size also correlates with the frequency of malignancy. Linda et al. reported that the malignancy detection rate was higher only in patients with enhancing lesions 0.6 cm or larger on MRI (18). IELs showed enhancement as focus/

foci (<5 mm), masses (three-dimensional lesion), and areas of nonmass enhancement (linear/ductal/segmental/clumped). Regarding the enhancement pattern of the lesions, 109 (68.55%) masses, 44 (27.68%) nonmasses, and 6 (3.77%) focus/foci enhancements were noted. The detection rate was higher for mass than for nonmass lesions and correlated with lesion size for mass lesions only. In sonographically undetectable lesions, the vast majority were nonmass IELs (n=17, 77.27%). Fifty-two percent of biopsied IELs were nonmass-enhanced lesions (n=48). Numerous studies suggest that US correlation is more likely for MRI-detected breast lesions that appear as masses on MRI than those that appear as foci or nonmass lesions (15-19).

Candelaria and Fornage (20) found that a US visualization correlation was more likely when MRI-detected lesions appeared as foci (67%) or masses (73%) than when they appeared as nonmass lesions observed on MRI (54%). Demartini et al (21) found that a US correlation was more likely for MRI-detected lesions described as masses (58%) than for those described as foci (37%) or nonmass lesions (30%). Meissnitzer et al (22) reported that a US correlation was more likely for masses (62%) than for nonmasses (31%). The multiplicity, bilaterality, and multifocality of IELs influence treatment strategies (upfront surgery/neoadjuvant chemotherapy), surgical planning (mastectomy/breast-conserving surgery), and prognosis. In our study, most of the IELs were ipsilateral with known BC (61.00%) and unifocal (62.26%). Of histopathologically confirmed contralateral lesions, 22 (36.66%) were benign, and 11 (35.48%) were malignant. Similar to our study population, women with unilateral breast cancer experience a prevalence of synchronous contralateral cancer of approximately 1% to 4% and an annual risk of contralateral breast cancer of approximately 0.4% per year (23-25). Therefore, information about the opposite breast in BC patients has enormous significance for clinical decision-making and patient management. In our series, contralateral malignancies predominantly consisted of DCIS (n=7, 38.89%), while four lesions (30.77%) were invasive cancer. A correlation was more likely when IELs appeared as foci or masses than when they appeared as nonmass lesions on MRI. Additionally, IELs described as masses correlate to those described as foci or nonmass lesions (19-21). Nonmass enhancement was primarily observed in DCIS (Figure 2A, 2B). A total of 34.06% of IELs were histopathologically diagnosed as synchronous malignancies (Figure 2C, 2D).

Our study used MRI BI-RADS lexicon to classify the 159 IELs, with 45 (28.13%) being classified as BIRADS, three (probably benign), and 91 (57.23%) being classified as BIRADS 4 (suspicious). Linda et al found that the malignancy rate of MRI-detected lesions increased as the analogous MRI BI-RADS category increased. Additionally, the frequency of malignancy proved to be higher in patients with a history of breast cancer, particularly in the case of synchronous neoplasm and when the incidental lesion was ipsilateral to the index tumor (18,19).

The SLUS-correlated lesions were classified by using US BI-RADS lexicon. Of the categories assigned, 16 (14.16%) were Category 2 (benign), 36 (31.86%) were Category 3 (probably benign), and 61 (53.98%) were Category 4 (suspicious). Hellerhoff et al. reported that, depending on lesion size and type, the negative predictive value (NPV) of SLUS is approximately 88%, which helps down grade MRI BI-RADS Category 4 lesions (4). Overall, the results of our study suggest that SLUS can be a complementary modality in detecting and evaluating IELs in patients with breast cancer. CE-bMRI is more sensitive for detecting IELs, but SLUS can provide additional information about lesion size, morphology, and vascularity. Additionally, it is crucial to correlate the imaging findings with the clinical presentation and other imaging studies, such as mammography, when making decisions about biopsy and treatment.

Limitations:

Our study has limitations because it is a retrospective monocentric observational study and lacks subgroup analyses of each parameter.

CONCLUSION

In conclusion, SLUS can be a valuable tool in assessing lesions initially detected on breast MRI. It can help to reduce the number of unnecessary biopsies. A negative or benign SLUS finding can safely exclude malignancy in most cases. Developing reliable management guidelines for these lesions may require further studies with larger series of cases and detailed subgroup analyses. Synchronous contralateral breast cancer risk should be considered for the preoperative evaluation of primary operable breast cancer patients.

Conflict of Interest: No conflicts of interest to declare.

Ethics Committee Approval: This study was conducted following the principles of the Helsinki Declaration, and the study protocol was approved by the the Institutional Review Board of Haydarpasa Numune Research and Training Hospital (file date and number: 2021/168-3339).

Financial Disclosure: There is no funding of this study.

Peer-review: Externally peer-reviewed.

Authorship Contributions: Design of the study; -Supervision; -Data collection & processing; -Performed data analysis; -Literature search; -Written by; -Critical review; S.A.A.

References

- Warner E, Messersmith H, Causer P, Eisen A, Shumak R, Plewes D. Systematic review: using magnetic resonance imaging to screen women at high risk for breast cancer. *Ann Intern Med.* 2008; 148:671–9.
- Ryu HH, Kim EY, Park YL, Park CH. The predictive value of second-look ultrasound after preoperative breast magnetic resonance imaging. *J Breast Dis.* 2015;3:65–70.
- Houssami N, Ciatto S, Macaskill P, Lord SJ, Warren RM, Dixon JM, et al. Accuracy and surgical impact of magnetic resonance imaging in breast cancer staging: systematic review and meta-analysis in detection of multifocal and multicentric cancer. *J Clin Oncol.* 2008;26:3248–58.
- Hellerhoff K, Dietrich H, Schinner R, Rjosk-Dendorfer D, Sztórkay-Gaul A, Reiser M, et al. Assessment of MRI-detected breast lesions: A benign correlate on second-look ultrasound can safely exclude malignancy. *Breast Care (Basel).* 2021;16:435–43.
- Jobsen JJ, van der Palen J, Ong F, Meerwaldt JH. Synchronous, bilateral breast cancer: prognostic value and incidence. *Breast.* 2003;12:83-8.
- Heron DE, Komarnicky KT, Hyslop T, Schwartz GF, Mansfield CM. Bilateral breast carcinoma: risk factors and outcomes for patients with synchronous and metachronous disease. *Cancer.* 2000; 88:2739–50.
- Hungness ES, Safa M, Shaughnessy EA, Aron BS, Gazder PA, Hawkins HH, et al. Bilateral synchronous breast cancer: mode of detection and comparison of histologic features between the 2 breasts. *Surgery.* 2000;128:702–7.
- Kim TH, Kang DK, Jung YS, Kim KS, Yim H. Contralateral enhancing lesions on magnetic resonance imaging in patients with breast cancer: Role of second-look sonography and imaging findings of synchronous contralateral cancer. *J Ultrasound Med.* 2012;31:903–13.
- Wu WP, Chen CY, Lee CW, Wu HK, Chen ST, Wu YT, et al. Impact of pre-operative breast magnetic resonance imaging on contralateral synchronous and metachronous breast cancer detection-A case control comparison study with 1468 primary operable breast cancer patients with mean follow-up of 102 months. *PLoS One.* 2021;16:e0260093.
- Perlet C, Heywang-Kobrunner SH, Heinig A, Sittke H, Casselman J, Anderson I, et al. Magnetic resonance-guided, vacuum-assisted breast biopsy: results from a European multicenter study of 538 lesions. *Cancer.* 2006;106:982–90.
- Hong MJ, Cha JH, Kim HH, Shin HJ, Chae EY, Shin JE, et al. Second-look ultrasonography for MRI-detected suspicious breast lesions in patients with breast cancer. *Ultrasonography.* 2015;34:125–32.
- Park VY, Kim MJ, Kim E-K, Moon HJ. Second-look US: How to find breast lesions with a suspicious MR imaging appearance. *Radiographics.* 2013;33:1361–75.
- Abe H, Schmidt RA, Shah RN, Shimauchi A, Kulkarni K, Sennett CA, et al. MR-directed (“Second-Look”) ultrasound examination for breast lesions detected initially on MRI: MR and sonographic findings. *AJR Am J Roentgenol.* 2010;194:370–7.
- Alikhassi A, Li X, Au F, Kulkarni S, Ghai S, Allison G, et al. False-positive incidental lesions detected on contrast-enhanced breast MRI: clinical and imaging features. *Breast Cancer Res Treat.* 2023;198:321-34.
- Kolta M, Clauser P, Kapetas P, Bernathova M, Pinker K, Helbich TH, et al. Can second-look ultrasound downgrade MRI-detected lesions? A retrospective study. *Eur J Radiol.* 2020;127:108976.
- Mazzei MA, Di Giacomo L, Fausto A, Gentili F, Mazzei FG, Volterrani L. Efficacy of Second-Look Ultrasound with MR Coregistration for Evaluating Additional Enhancing Lesions of the Breast: Review of the Literature. *Biomed Res Int.* 2018:1–8.
- Jeon T, Kim YS, Son HM, Lee SE. Tips for finding magnetic resonance imaging-detected suspicious breast lesions using second-look ultrasonography: a pictorial essay. *Ultrasonography.* 2022;41:624–32.
- Linda A, Zuiani C, Londero V, Bazzocchi M. Outcome of initially only magnetic resonance mammography-detected findings with and without correlate at second-look sonography: distribution according to patient history of breast cancer and lesion size. *Breast.* 2008;17:51–7.
- Kwon YG, Park AY. Scoring System to Predict Malignancy for MRI-Detected Lesions in Breast Cancer Patients: Diagnostic Performance and Effect on Second-Look Ultrasonography. *Taehan Yongsang Uihakhoe Chi.* 2020;81:379-94.
- Candelaria R, Fornage BD. Second-look US examination of MRdetected breast lesions. *J Clin Ultrasound.* 2011;39:115-21.
- Demartini WB, Eby PR, Peacock S, Lehman CD. Utility of targeted sonography for breast lesions that were suspicious on MRI. *AJR Am J Roentgenol.* 2009;192:1128-34.

22. Meissnitzer M, Dershaw DD, Lee CH, Morris EA. Targeted ultrasound of the breast in women with abnormal MRI findings for whom biopsy has been recommended. *AJR Am J Roentgenol.* 2009;193:1025-9.
23. Giannakeas V, Lim DW, Narod SA. The risk of contralateral breast cancer: a SEER-based analysis. *Br J Cancer.* 2021;125:601-10.
24. Tong J, Tan D, Ma J, Hu Y, Li M. Nomogram to predict contralateral breast cancer risk in breast cancer survivors: A SEER-based study. *Medicine (Baltimore).* 2021;100:e27595.
25. Ramin C, Withrow DR, Davis Lynn BC, Gierach GL, Berrington de González A. Risk of contralateral breast cancer according to first breast cancer characteristics among women in the USA, 1992-2016. *Breast Cancer Res.* 2021;23:24.